

# Prolonged Video-EEG in Identifying Paroxysmal Nonepileptic Events in Children With Epilepsy: A Useful Tool

Aman P. S. Sohal, Arif Khan, and Nahin Hussain

**Purpose:** Habitual events, behaviors, and nonepileptic events can be easily confused with epileptic seizures in children in the absence of clear description and can be challenging, even for an experienced clinician. The aim was to report on the usefulness of adding video-EEG to routine EEG studies of infants and children with frequent atypical paroxysmal events.

**Methods:** A retrospective analysis of video-EEG carried over a 2-year period in a tertiary pediatric neurology center. Outcomes were classified as: “conclusive epileptic,” “conclusive nonepileptic,” “unremarkable,” and “inconclusive.”

**Results:** Forty-four children (M:F 19:25) with an age range of 1 to 15 years (mean: 7 years, median: 8.5 years) were analyzed. Thirty (68%) children had successful epilepsy classification. A diagnosis of a specific nonepileptic event was reached in 55% of cases. Antiepileptic drugs were discontinued completely in 8 patients (20%), and the total number of antiepileptic drugs was reduced in 13 others (33%).

**Conclusions:** Paroxysmal nonepileptic events can cause diagnostic confusion, particularly in children with developmental delay, epilepsy (especially refractory epilepsy), or those with previous “abnormal” EEG. Accurate diagnosis can be reached in the majority of cases using prolonged video-EEG monitoring.

**Key Words:** Video-EEG, Nonepileptic events, Children.

(*J Clin Neurophysiol* 2014;31: 149–151)

Habitual events and behaviors can be easily confused with epileptic seizures in children in the absence of clear description and can be challenging even for an experienced clinician. Children with epilepsy are especially prone to paroxysmal events that can pose significant diagnostic dilemma. The events witnessed in children may be atypical, history from parents and witnesses may not be accurate, interictal EEG may be normal or contain nonspecific abnormalities, and misdiagnosis of a paroxysmal event as an epileptic seizure is common. Frequently, parental reports of “seizure” lead to initiation, increase, or change of antiepileptic drugs (AEDs) without a clear understanding of the underlying process. Correct diagnosis of such events is important not only to ensure that the epileptic seizures are recognized and treated promptly, but also to avoid the irrational and potentially harmful use of AEDs to control nonepileptic (NE) events. Video-EEG (v-EEG) monitoring is the diagnostic modality that could answer these questions, and it plays a central role in the management of children with epilepsy (Asano et al., 2001; Bye et al., 2000; Kotagal et al., 2002). We studied the utility of

adding video telemetry to routine EEG studies of epileptic children with frequent atypical paroxysmal events.

## METHODS

We conducted a retrospective analysis of v-EEG carried out in tertiary pediatric neurology setting during a 2-year period from October 2004 to October 2006. The decision whether to add video recording was made by the pediatric neurologist, when there was a diagnostic doubt about paroxysmal events of unclear etiology reported by the child, parent, or caretakers. All children, who had previously been diagnosed with epilepsy, had to have paroxysmal events on a frequent basis and were on AEDs.

We reviewed the medical records, previous EEGs, the history provided by the child and parent, parent record sheets, and v-EEG. All children had minimum of 24 hours (range, 1–5 days) of consecutive EEG recordings with scalp electrodes and simultaneous video monitoring on a 16-channel cable video telemetry using the international 10–20 system. Electrocardiogram and other physiological parameters such as oxygen saturations and blood pressure were also recorded when indicated. Antiepileptic drugs were reduced or discontinued on admission as necessary to capture a sufficient number of paroxysmal events. Parent or the caretaker stayed with the child throughout the recording and pressed a buzzer, which was recorded as an event on the EEG trace each time they perceived that the child had a paroxysmal event. Both parents and medical staff assisted in documenting and time logging the event. Decision to stop recording was made once sufficient number of typical paroxysmal events had occurred and sufficient EEG data obtained. All v-EEG were analyzed by a team of consultant Paediatric Neurologist, Clinical Neurophysiologist, and EEG technician.

Outcomes were classified as: “conclusive epileptic” (successful classification of epilepsy), “conclusive NE” (demonstration of NE habitual event), “unremarkable” (normal EEG without habitual events captured), and “inconclusive” (inability to clarify the nature of habitual events with abnormal interictal EEG findings). An event was regarded as NE, when based on the clinical features and absence of epileptiform paroxysmal activity, which is diagnostic of a seizure at the time of the event. Epileptic events were classified as generalized or focal, and the seizure type was further described. Nonepileptic events were further classified into physiological, behavioral, or psychogenic based on combination of data from v-EEG recording and clinical history. We defined physiological events as overinterpretation of normal phenomena (e.g., startle, posturing, syncope, sleep myoclonus, and sleep arousal).

Behavioral events were described as benign stereotypical events in which there was no evidence of secondary gain (e.g., tics, shuddering, blinking, hyperventilation, and self-stimulating behavior). Psychogenic were those associated with secondary gain. After NE events were identified, therapeutic regimens were examined to

From the Department of Pediatric Neurology, Leicester Royal Infirmary, Leicester, United Kingdom.

Address correspondence and reprint requests to Aman P. S. Sohal, MRCPCH, Department of Pediatric Neurology, Leicester Royal Infirmary, Leicester, United Kingdom LE1 5WW; e-mail: manusohal@doctors.org.uk.

Copyright © 2014 by the American Clinical Neurophysiology Society  
ISSN: 0736-0258/14/3102-0149

determine if proper diagnosis resulted in simplification of AED regimen or in redirection into appropriate therapies.

### RESULTS

Forty-four children (M:F 19:25) with an age range of 1 to 15 years (mean: 7 years, median: 8.5 years) had video telemetry. The mean length of stay was 2.5 days (range, 1–5 days). A total of 1628 paroxysmal events were logged and every patient had at least three paroxysmal episodes recorded during the v-EEG. Of these, 884 (54%) were NE events. We identified epileptic seizure in 33 (75%) children, purely NE events in 11 children (25%), and both epileptic and NE events in 25 children (57%).

Thirty (68%) children had successful epilepsy classification, and 8 (18%) had NE events with no corresponding EEG changes (Fig. 1). Epilepsy classification was changed in 8 children after v-EEG, of which 2 children were reclassified as Lennox–Gastaut Syndrome, and 1 each as Juvenile Myoclonic epilepsy and Dravet Syndrome. One patient who was previously “unclassified” were given a classification diagnosis. The details of these are outlined in Fig. 2. Nine children had behavioral events, 9 physiological events, and 1 psychogenic NE event. The major subgroups of NE events were staring/daydreaming, sleep phenomena (arousal)—night terrors, syncope, motor tics, ritualistic movements, and shuddering (Table 1). Based on the identification of NE events, AEDs were discontinued completely in 8 (18%) patients, and the total number of AEDs was reduced in 13 (30%) others.

### DISCUSSION

Prolonged v-EEG has long been used in the evaluation of paroxysmal events in children (Asano et al., 2005; Kim et al., 2012; Riquet et al., 2011; Watemberg et al., 2005). The frequency of paroxysmal NE events in pediatric population ranges from 3.5% to 43% in various epilepsy centers (Kutluay et al., 2010; Patel et al., 2007). The necessity for prolonged v-EEG monitoring relates largely to the chance of capturing sufficient episodes to permit correlation of clinical and EEG data. Children in our study were known to have epilepsy and had a short v-EEG interictal 30-minute recording, which did not capture the paroxysmal events in question before having a prolonged v-EEG. Epileptic and paroxysmal NE events are often seen in coexistence in same patient; therefore, simultaneous EEG monitoring along with video is the gold standard to differentiate epileptic and NE events. Furthermore, abnormalities on interictal recordings are particularly common in children with both epileptic and NE, which emphasize the need for prolonged time logged v-EEG to identify the true nature of the paroxysmal events.

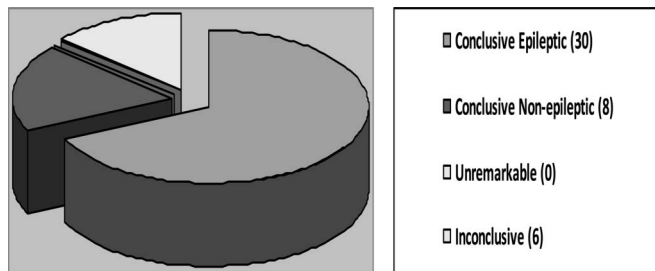


FIG. 1. Classification of outcomes of video-EEG.

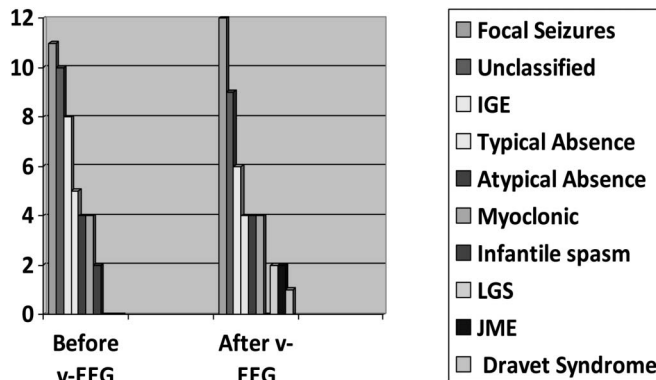


FIG. 2. Seizure classification before and after video-EEG.

Our study demonstrated that NE events are quite frequent and can be easily “mislabelled” as epilepsy. All patients had at least three paroxysmal episodes recorded during the prolonged v-EEG study similar to those reported in other prolonged studies (Duchowny et al., 1988). Our study identified 54% of the paroxysmal events as NE, of which staring was the most common NE event (32%), which was higher than previous studies (12%–40%) (Asano et al., 2005; Bye et al., 2000; Kim et al., 2012; Metrick et al., 1991). The possible reasons for this could be a smaller cohort, longer duration of v-EEG as compared with previous studies, and development delay, large proportion (60%) of children. The basis for misdiagnosis was usually parental or caretaker’s misinterpretation of behaviors. Occasionally, obtaining a good history or observation of the paroxysmal events alone can help, but often the distinction between epileptic and NE episodes could be made only after careful review of simultaneous v-EEG monitoring especially in children who have epilepsy and psychomotor delay.

Prolonged v-EEG also helps in epilepsy classification because many children are unclassified in the absence of clearly defined seizure type and correlated EEG findings. One large study, which included 1000 children with v-EEG monitoring successfully classified epilepsy in 31% of their cohort. Our study helped in the reclassification of seizure type in 8 (18%) children. Of note, were the children previously labeled as “idiopathic generalized epilepsy,” “infantile spasms,” and typical absence epilepsy. These children were reclassified as juvenile myoclonic epilepsy, SMIE (severe myoclonic epilepsy of infancy, Dravet syndrome), Lennox–Gastaut Syndrome, idiopathic focal epilepsy. One child who was previously unclassified were successfully given ILAE classification.

Previous studies have demonstrated that poor response to treatment may be as a result of incorrect diagnosis rather than inappropriate choice of AEDs (Nousiainen et al., 1992). Our study highlights the importance of v-EEGs in reduction of unnecessary AEDs after correct diagnosis. Identification of NE events led to

TABLE 1. Description of Nonepileptic Events

Nonepileptic Event	Number (%)
Staring/daydreaming	155 (32)
Syncope	97 (20)
Night terrors	72 (15)
Motor stereotypies	73 (15)
Motor tics	54 (11)
Shuddering	34 (7)

the reduction of AEDs in 30% and discontinued completely in 18% of our patients. This is in comparison with previous studies that quote alteration of treatment in 45% patients and termination of treatment in 3% patients (Chen et al., 1995). Thus, recognition of NE events had a significant impact on treatment plans and helped us to counsel parents about the true nature of the paroxysmal events.

In conclusion, paroxysmal NE events can cause diagnostic confusion, particularly in children with developmental delay, epilepsy (especially refractory epilepsy), or those with previous epileptiform abnormalities on EEG. Accurate diagnosis can be reached in the majority of cases using prolonged v-EEG monitoring. A diagnosis of NE events should be considered in all children with refractory seizures or multiple seizure types. We therefore recommend prolonged v-EEG monitoring in all children with epilepsy where a clinician is faced with diagnostic uncertainty.

#### REFERENCES

- Asano E, Chugani DC, Juhasz C, et al. Surgical treatment of West Syndrome. *Brain Dev* 2001;23:668–676.
- Asano E, Pawlak C, Shah A, et al. The diagnostic value of initial video-EEG monitoring in children—review of 1000 cases. *Epilepsy Res* 2005;66:129–135.
- Bye AM, Kok DJ, Ferschild FT, Vles JS. Paroxysmal non-epileptic events in children: a retrospective study over a period of 10 years. *J Paediatr Child Health* 2000;36:244–248.
- Chen LS, Mitchell WG, Horton EJ, Snead OC III. Clinical utility of video-EEG monitoring. *Pediatr Neurol* 1995;12:220–224.
- Duchowny MS, Resnick TJ, Deray MJ, Alvarez LA. Video EEG diagnosis of repetitive behavior in early childhood and its relationship to seizures. *Pediatr Neurol* 1988;4:162–164.
- Kim SH, Kim H, Lim BC, et al. Paroxysmal nonepileptic events in pediatric patients confirmed by long-term video-EEG monitoring—Single tertiary center review of 143 patients. *Epilepsy Behav* 2012;24:336–340.
- Kotagal P, Costa M, Wyllie E, Wolgamuth B. Paroxysmal non epileptic events in children and adolescents. *Pediatrics* 2002;110:e46.
- Kutluay E, Selwa L, Minecan D, et al. Nonepileptic paroxysmal events in a pediatric population. *Epilepsy Behav* 2010;17:272–275.
- Metrick ME, Ritter FJ, Gates JR, et al. Nonepileptic events in childhood. *Epilepsia* 1991;32:322–328.
- Nousiainen U, Suomalainen T, Mervaala E. Clinical benefits of scalp EEG studies in intractable seizure disorders. *Acta Neurol Scand* 1992;85:181–186.
- Patel H, Scott E, Dunn D, Garg B. Nonepileptic seizures in children. *Epilepsia* 2007;48:2086–2092.
- Riquet A, Lamblin MD, Bastos M, et al. Usefulness of video-EEG monitoring in children. *Seizure* 2011;20:18–22.
- Waternberg N, Tziperman B, Dabby R, et al. Adding video recording increases the diagnostic yield of routine electroencephalograms in children with frequent paroxysmal events. *Epilepsia* 2005;46:716–719.