

Images in...

## Arachnoid cysts: are they always incidental?

Sushil Beri,<sup>1</sup> Arif Khan,<sup>1</sup> Jayaprakash Gosalakkal,<sup>2</sup> Arani V Sridhar<sup>2</sup><sup>1</sup>Children's Hospital, Leicester, UK;<sup>2</sup>Leicester Royal Infirmary, Children's Hospital, Leicester, UK**Correspondence to** Dr Arani V Sridhar, arani.sridhar@uhl-tr.nhs.uk

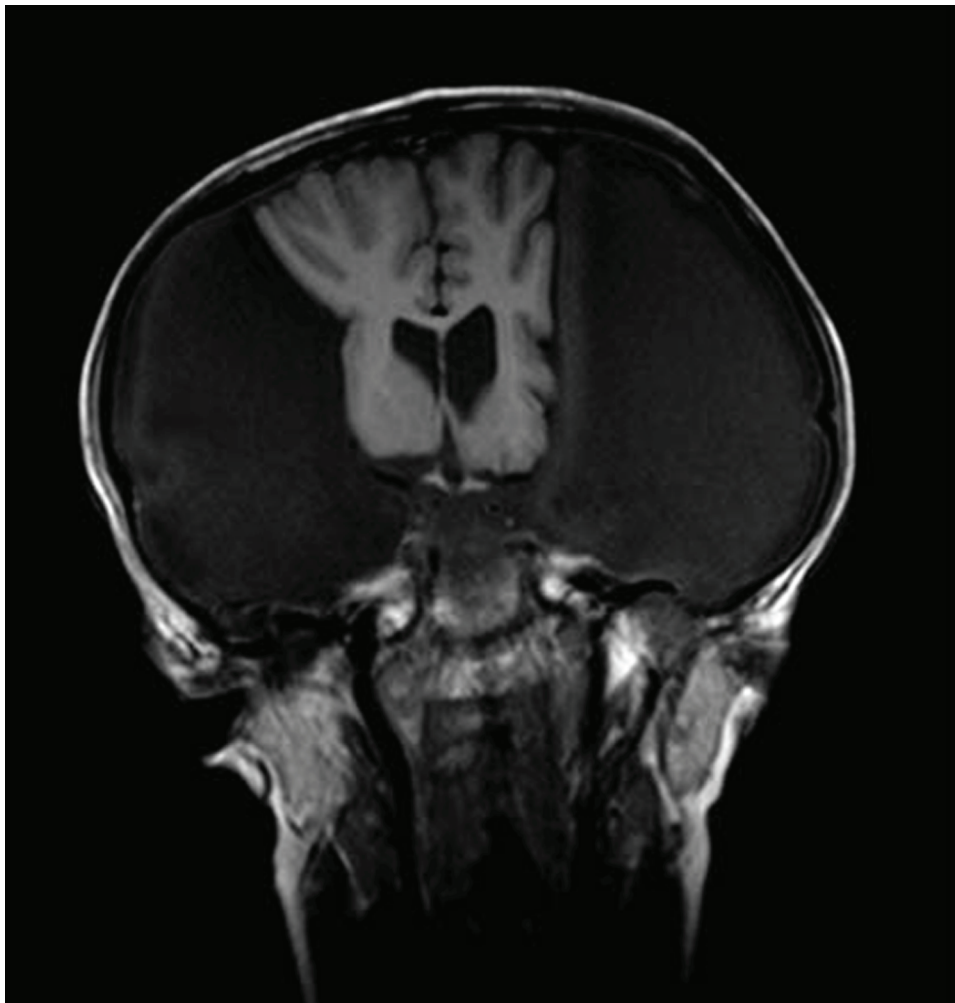
### DESCRIPTION

A 12-year-old young girl presented with progressively worsening, generalised, chronic daily headaches for nearly 18 months. There were no vomiting, visual or sensory symptoms. Headaches were not associated with any postural variation or symptoms suggestive of intracranial hypertension. She had a history of chronic rhinitis. Concerns were also raised regarding her short-term

memory, both by school and parents. She had also been diagnosed with dyslexia.

Head circumference was 65 cm with temporo-parietal bossing. There was no papilloedema and neurological examination was unremarkable.

MRI brain (figure 1) revealed large, bilateral, middle cranial fossa arachnoid cysts, overlying the cerebral hemispheres. She underwent bilateral cyst decompression via



**Figure 1** T1 weighted coronal view of MRI brain showing large, bilateral, extra-axial arachnoid cysts overlying both cerebral hemispheres, extending into the middle cranial fossa and compressing on the adjacent cerebral hemispheres. There is associated mild scalloping of the overlying calvarium.

burr hole surgery leading to partial improvement in her symptoms.

Arachnoid cysts are non-tumorous, intra-arachnoid fluid collections and account for 1% of all intracranial space-occupying lesions.<sup>1</sup> They are often an incidental finding in children who are scanned for various reasons and more common in boys. Majority are supra-tentorial (90%) and usually detected in the first two decades of life. They can be either primary (congenital) or secondary after trauma, infection or haemorrhage.<sup>2</sup>

They may be symptomatic as they enlarge and interfere with adjacent structures or cerebrospinal fluid circulation leading to headaches, large head, hydrocephalus, seizures or endocrine problems and cognitive decline, based on the

topographical location. Conservative management is recommended, except in rare symptomatic cysts.<sup>3</sup>

**Acknowledgements** Neuro-surgical team at QMC, Nottingham

**Competing interests** None.

**Patient consent** Obtained.

### REFERENCES

1. **Clemenceau S**, Carpentier A. [Intracranial arachnoid cysts. A review]. *Rev Neurol (Paris)* 1999;**155**:604–8.
2. **Gosalakkal JA**. Intracranial arachnoid cysts in children: a review of pathogenesis, clinical features, and management. *Pediatr Neurol* 2002;**26**:93–8.
3. **Cincu R**, Agrawal A, Eiras J. Intracranial arachnoid cysts: current concepts and treatment alternatives. *Clin Neurol Neurosurg* 2007;**109**:837–43.

This pdf has been created automatically from the final edited text and images.

Copyright 2011 BMJ Publishing Group. All rights reserved. For permission to reuse any of this content visit <http://group.bmj.com/group/rights-licensing/permissions>.

BMJ Case Report Fellows may re-use this article for personal use and teaching without any further permission.

Please cite this article as follows (you will need to access the article online to obtain the date of publication).

Beri S, Khan A, Gosalakkal J, Sridhar AV. Arachnoid cysts: are they always incidental?. *BMJ Case Reports* 2011;10.1136/bcr.06.2011.4348, date of publication

Become a Fellow of BMJ Case Reports today and you can:

- ▶ Submit as many cases as you like
- ▶ Enjoy fast sympathetic peer review and rapid publication of accepted articles
- ▶ Access all the published articles
- ▶ Re-use any of the published material for personal use and teaching without further permission

For information on Institutional Fellowships contact [consortiasales@bmjgroup.com](mailto:consortiasales@bmjgroup.com)

Visit [casereports.bmj.com](http://casereports.bmj.com) for more articles like this and to become a Fellow